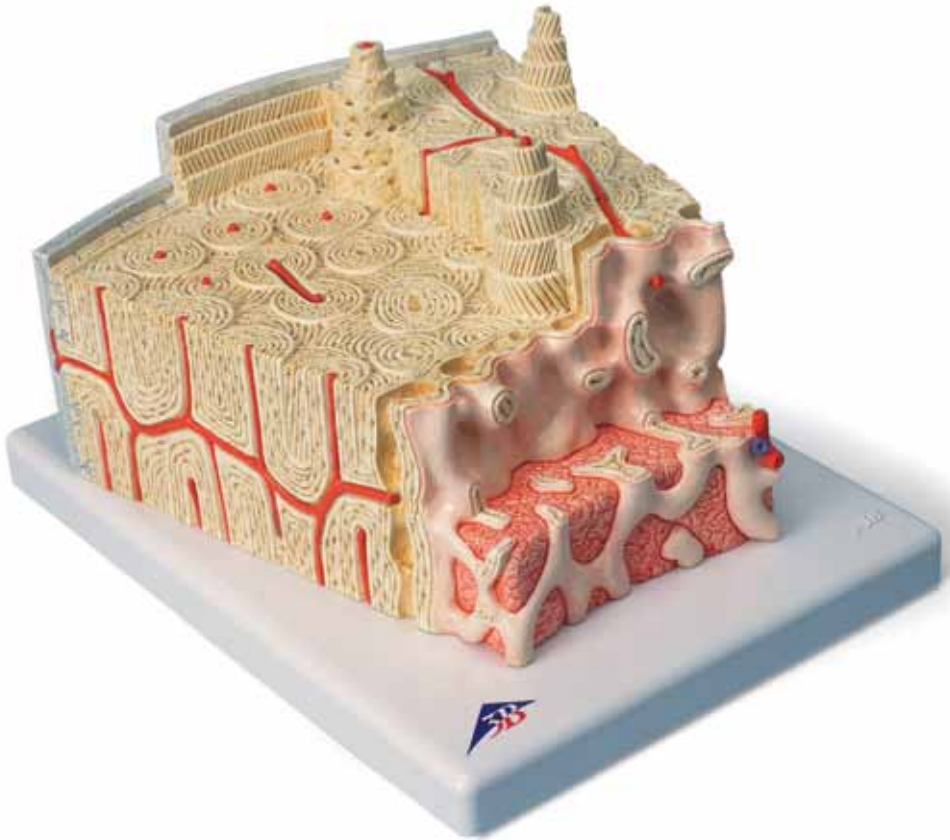




...going one step further



A79

(1000154)

Latin

- 1 Substantia trabecularis
- 2 Substantia compacta
- 3 Periosteum
- 4 Fibrae perforantes
- 5 Lamella circumferentialis externa
- 6 Osteon
- 7 Lamellae osteoni
- 8 Osteocytus
- 9 Vasa sanguinea (osteon)
- 10 Lamella interstitialis
- 11 Canalis perforans
- 12 Lamella circumferentialis interna
- 13 Endosteum
- 14 Medulla ossium (substantia spongiosa)



Bone Structure Model

English

This model shows a section of a lamellar bone, as found in the human skeleton as a basic structure of a tubular bone (approx. 80 times enlarged).

Compared to other bone types, tubular bones contain few bone trabeculae (spongy substance or *substantia spongiosa*) (1) and a thick compact layer (compact substance or *substantia compacta*) (2). The bone is covered by a membrane, the periosteum (3). The inner layer of the periosteum (osteogenic layer) consists of many cells and contains resting precursor cells of the bone cells (osteoblasts) that ensure regeneration in case of bone fractures. The outer layer is made of firm, collagenous connective tissue (fibrous layer). Bundles of collagenous fibers pass directly from the periosteum into the connective tissue of the bone (perforating fibers, Sharpey fibers) (4).

The next layer is the cortical layer (*substantia corticalis*) with its lamellar stratification of the intercellular substance (thus lamellar bone). Located at the very outside are the circumferential lamellae (5) running parallel to the periosteum. The basic structure of the lamellar bone is formed by the osteons, also referred to as Haversian systems (6). The lamellae are layers of anorganic substance (approx. 65 % of the complete substance), mainly hydroxyapatite, and organic substance (over 90 % collagen). Since the collagen fibers of the individual lamellae of an osteon run at various, respectively opposite angles of inclination (7), the compound structure of organic and anorganic components is additionally stabilised against pull and push forces. The bone cells (osteocytes) (8) are located between the lamellae, held in lacunae. The cells are nourished by the Haversian vessels (9), because all osteocytes are linked to one another and with the Haversian canal through canaliculi containing their cell extensions. The intermediate lamellae are located between the Haversian systems (osteons) without any connection to blood vessels (10).

Their thickness and stratification corresponds to that of former Haversian systems, however, the Haversian systems have built up over them in the course of the continuous restructuring of the bone that also continues after the growth period. Running from the periosteum, the Volkmann canals contain vessels connecting the vessels of the Haversian canals (11). The Volkmann canals are bony canals that are not surrounded by circular lamellae, as opposed to the Haversian canals. The systematic order of the Haversian canals is not

disrupted by the transverse or oblique perforation through the Volkmann canals. The cortical layer is followed in a fluid transition by the trabecular layer (spongy substance or *substantia spongiosa*), a spongy trabecular structure consisting of thin plates and rods (1). In the direction of the medullary cavity, the bony substance is limited by the inner circumferential lamella (12) and the inner membrane called endosteum (13). The endosteum consists of a connection of flat cells that can form new bones. Red bone marrow (14) can be found between the spongy trabeculae of the bone ends, and yellow bone marrow or fatty marrow in the tubular part of the bone. We thank Prof. Richard H. W. Funk, MD, Director of the Institute of Anatomy of the Carl Gustav Carus Medical Faculty, Dresden, Germany, for his support in the development of this model.

Bone structure

- 1 Trabeculae of bone (spongy substance)
- 2 Compact substance or *substantia compacta*
- 3 Periosteum
- 4 Perforating fibers, Sharpey fibers
- 5 Outer circumferential lamella
- 6 Osteons
- 7 Lamellae of the osteons
- 8 Osteocytes
- 9 Haversian vessels
- 10 Intermediate lamellae
- 11 Volkmann canals
- 12 Inner circumferential lamella
- 13 Endosteum
- 14 Bone marrow (spongy substance)