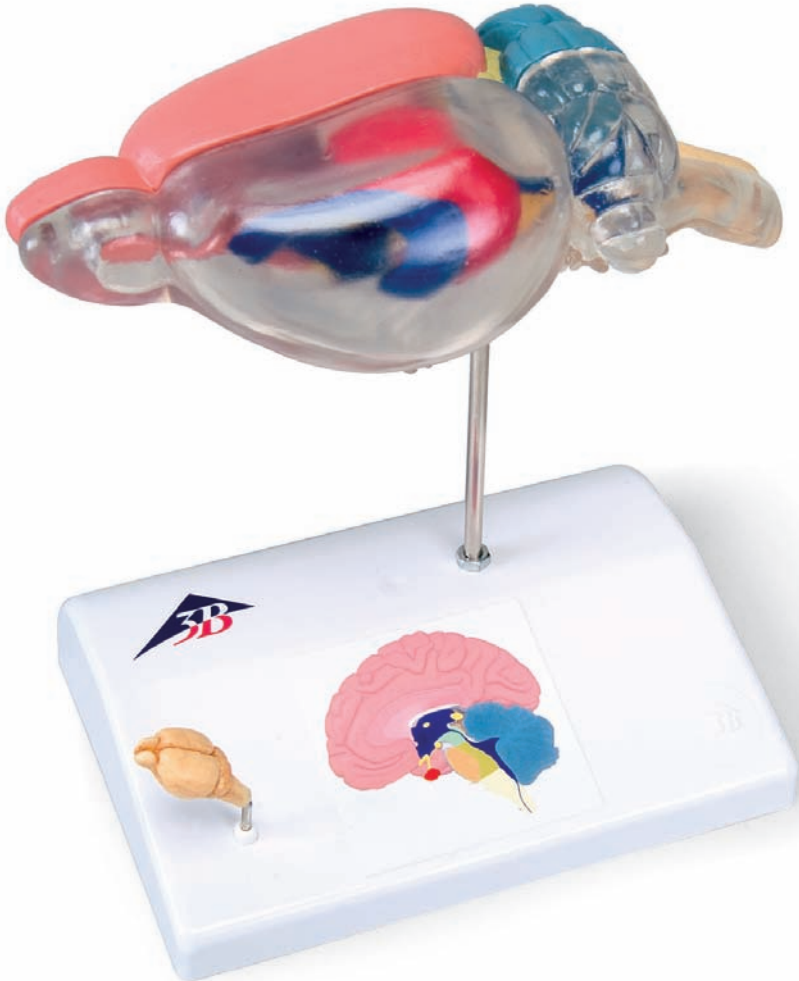




...going one step further



C29

Latin

Bild 1

- 1 Bulbus olfactorius
- 9 Ventriculi cerebri III und IV
- 10 Myelencephalon/Medulla oblongata
- 12 Diencephalon/Hypothalamus
- 14 Hypophyse
- 15 Chiasma opticum
- 16 N. abducens
- 17 N. trochlearis
- 18 N. oculomotorius
- 19 N. opticus
- 20 Pyramis Bulbi
- 22 Nn. Craniales IX und XII

Bild 2

- 3 Diencephalon/Thalamus
- 4 Ventriculi cerebri I und II
- 5 Hippocampus
- 6 Mesencephalon
- 7 Metencephalon
- 8 Cerebellum
- 10 Myelencephalon/Medulla oblongata
- 11 Pons
- 13 N. trigeminus
- 14 Hypophyse

Bild 3

- 2 Telencephalon
- 4 Ventriculi cerebri I und II
- 5 Hippocampus
- 6 Mesencephalon
- 8 Cerebellum
- 9 Ventriculi cerebri III und IV
- 10 Myelencephalon/Medulla oblongata
- 21 Paraflocculus (Cerebellum) Paraflocculus (Cerebellum)



Rat Brain for Comparative Anatomy

English

Fig. 1

- 1 Olfactory bulb
- 9 3rd and 4th ventricles of brain
- 10 Medulla oblongata
- 12 Hypothalamus
- 14 Pituitary gland
- 15 Optic chiasm
- 16 6th cranial nerve
- 17 4th cranial nerve
- 18 3rd cranial nerve
- 19 2nd cranial nerve
- 20 Pyramid
- 22 9th - 12th cranial nerves

Fig. 2

- 3 Diencephalon
- 4 1st and 2nd ventricle of brain
- 5 Hippocampus
- 6 Mesencephalon
- 7 Metencephalon
- 8 Cerebellum
- 10 Medulla oblongata
- 11 Pons (part of the ventral metencephalon)
- 13 5th cranial nerve 1,2,3
- 14 Pituitary gland

Fig. 3

- 2 Telencephalon
- 4 1st and 2nd ventricles of brain
- 5 Hippocampus
- 6 Mesencephalon
- 8 Cerebellum
- 9 3rd and 4th ventricles of brain
- 10 Medulla oblongata
- 21 Paraflocculus of the cerebellum



