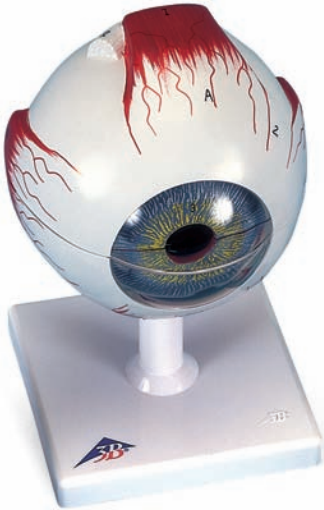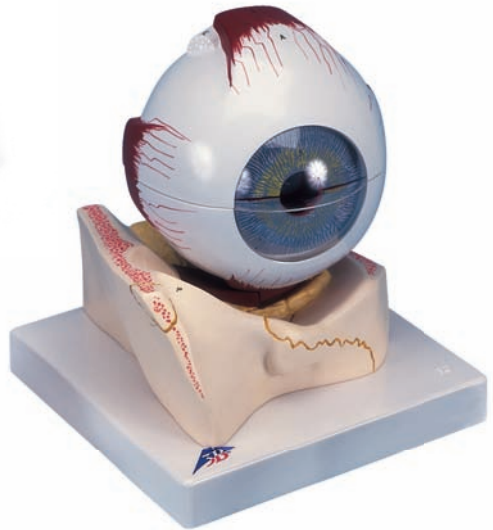




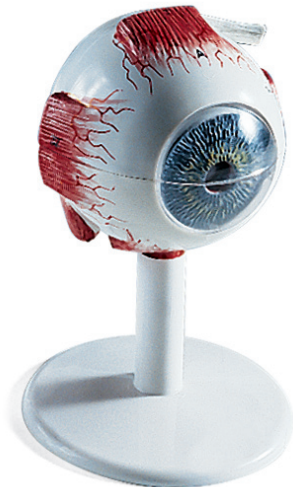*...going one step further*



F10



F11



F15

**F10**

**F11**

**F15**

**Latin**

**Musculi externi bulbi oculi**

- I M. rectus superior
- II M. rectus inferior
- III M. rectus medialis
- IV M. rectus lateralis
- V Tendo musculi obliqui superioris
- VI M. obliquus inferior

**A Tunica fibrosa bulbi**

- 1 Cornea
- 2 Sclera

**B Tunica vasculosa bulbi**

- 3 Iris cum pupilla
- 4 M. ciliaris
- 5 Corona ciliaris
- 6 Choroidea
- 7 Nn. ciliares
- 8 V. vorticososa
- 8a Aa.ciliares

**C Tunica interna bulbi**

- 9 Retina
- 10 Pars ciliaris retinae
- 11 Arteriolae retinae
- 12 Venulae retinae
- 13 Macula lutea et fovea centralis
- 14 Discus nervi optici
- 15 Lens
- 16 Corpus vitreum



# The human eye

English

**F10, F11 enlarged approx. 5 times**

**F15 enlarged approx. 3,5 times**

## **Extra-ocular muscles**

- I Superior rectus
- II Inferior rectus
- III Medial rectus
- IV Lateral rectus
- V Tendon of superior oblique
- VI Inferior oblique

## **A Fibrous layer of eyeball**

- 1 Cornea
- 2 Sclera

## **B Vascular layer of eyeball**

- 3 Iris with pupil
- 4 Ciliary muscle
- 5 Corona ciliaris
- 6 Choroid
- 7 Ciliary nerves
- 8 Vorticose vein
- 8a Ciliary arteries

## **C Inner layer of eyeball**

- 9 Retina
- 10 Ciliary part of retina
- 11 Retinal arterioles
- 12 Retinal venules
- 13 Macula and fovea centralis
- 14 Optic disc
- 15 Lens
- 16 Vitreous body

