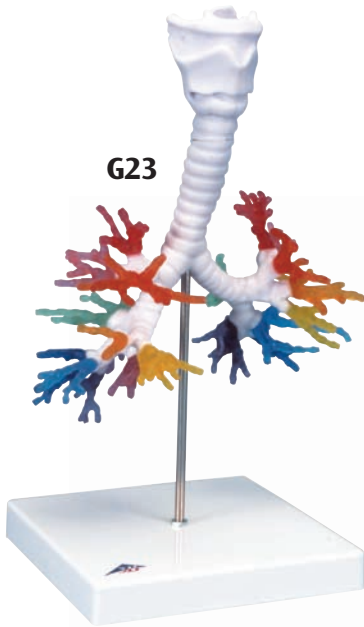
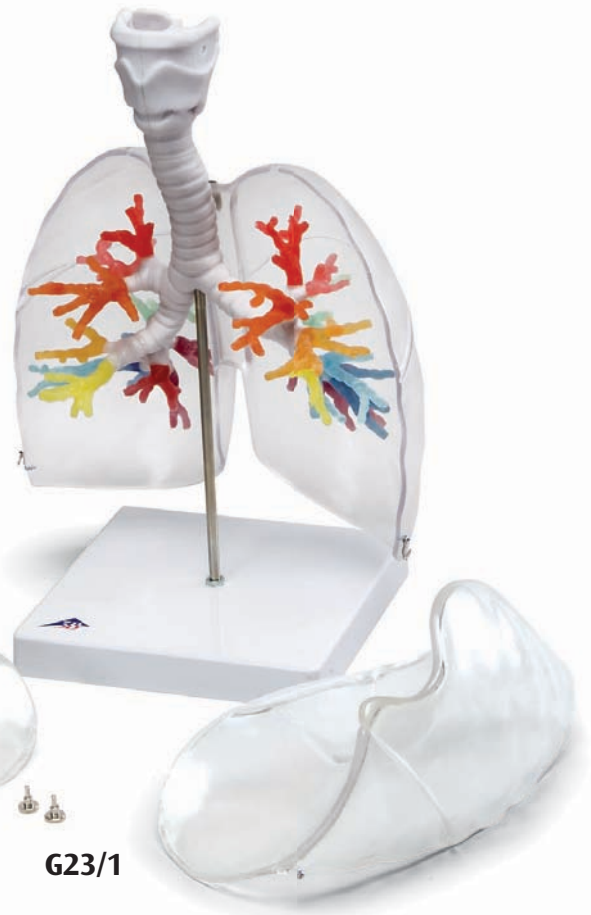



...going one step further



G23



G23/1

G23, G23/1

G23 CT Bronchial Tree with Larynx

English

This unique model was created on the basis of computer tomography data of a human (male, approx. 40 years). What is special about this procedure is that the natural spatial relations and the reciprocal location of the segmental bronchi can be preserved and demonstrated in a realistic way. Traditional procedures such as casts from a specimen or completely new models are always at the expense of the natural three dimensions. The larynx with hyoid bone and epiglottis and the trachea with primary and lobar bronchi are depicted in one color. The larynx is detachable at the level of the second tracheal cartilage and divisible in the median plane. The epiglottis is mounted flexibly. The various segmental bronchi are made of elastic material and depicted in various transparent colors so that they are easier to distinguish visually.

Right main bronchus (bronchus principalis dexter):

Right superior lobar bronchus (bronchus lobaris superior dexter)

- Red: B I, apical segmental bronchus
- Pink: B II, posterior segmental bronchus
- Orange: B III, anterior segmental bronchus

Right middle lobar bronchus (bronchus lobaris medius dexter)

- Golden yellow: B IV, lateral segmental bronchus
- Lemon yellow: B V, medial segmental bronchus

Right inferior lobar bronchus (bronchus lobaris inferior dexter)

- Green: B VI, superior segmental bronchus
- Mauve: B VII, medial basal segmental bronchus (cardiacus)
- Light blue: B VIII, anterior basal segmental bronchus
- Dark blue: B IX, lateral basal segmental bronchus
- Purple: B X, posterior basal segmental bronchus (on the model with double origin)

Left main bronchus (bronchus principalis sinister):

Left superior lobar bronchus (bronchus lobaris superior sinister)

- Red: B I, apicoposterior segmental bronchus
- Pink: B II, apicoposterior segmental bronchus
- Orange: B III, anterior segmental bronchus
- Golden yellow: B IV, superior lingular segmental bronchus
- Lemon yellow: B V, inferior lingular segmental bronchus

Left inferior lobar bronchus (bronchus lobaris inferior sinister)

- Green: B VI, superior segmental bronchus
- B VII, medial basal segmental bronchus (cardiacus), usually not developed (as in this model)
- Light blue: B VIII, anterior basal segmental bronchus
- Dark blue: B IX, lateral basal segmental bronchus
- Purple: B X, posterior basal segmental bronchus

The three-part model is mounted in its natural position on a base (detachable).

Instructions for care:

- Avoid excessive heat, e.g. prolonged direct exposure to sun.
- Clean the model with a dust brush or with mild soap solutions.

G23/1 CT Bronchial Tree with Larynx and Transparent Lungs

In addition to the bronchial tree created from computer tomography data, this model shows the right and left lungs.

The left lung consists of two lobes, an upper and a lower lobe, which are separated by a fissure that runs obliquely (oblique fissure of lung).

The right lung, in contrast, is made up of three lobes: an upper, a middle and a lower lobe. From a posterior view, only the upper and lower lobes can be seen. The wedge-shaped middle lobe is located anteriorly between the upper and lower lobes. An oblique fissure runs posteriorly between the upper and lower lobes and lateroanteriorly between the middle and lower lobes. A fissure running horizontally (horizontal fissure of right lung) separates the upper and middle lobes lateroanteriorly.

Due to the transparency of the lungs and the depiction of the lobar fissures, the assignment of the segmental bronchi to the respective lobes of the left and right lungs can be studied from the outside.

A frontal section at the entrance point level of the vessels and bronchi (hilum of lung) allows division of the lungs.

We would like to thank Prof. Dr. med. Richard H.W. Funk, Head of the Institute of Anatomy of the Medical Department Carl Gustav Carus, Dresden/Germany, for his support in developing this model.

