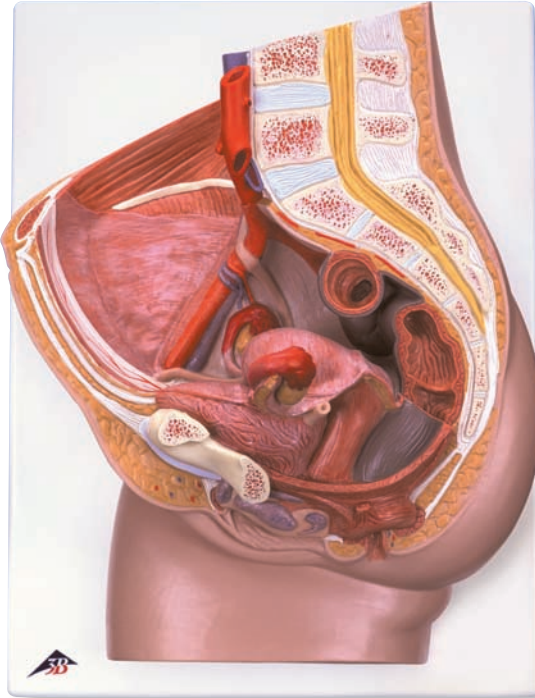
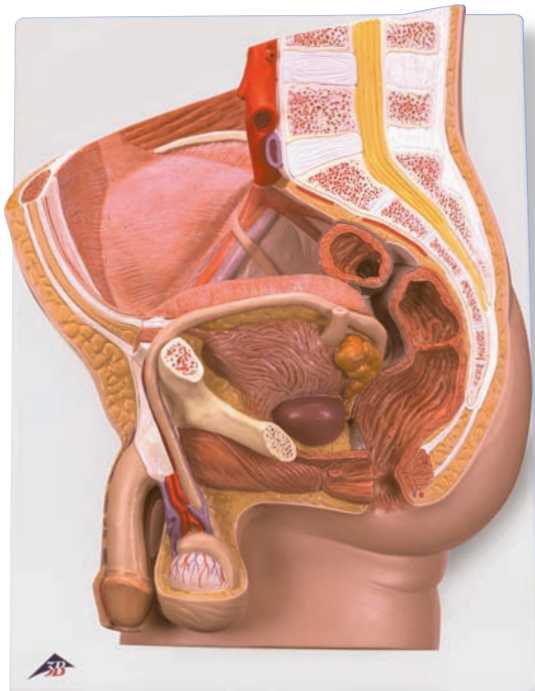




...going one step further



H10



H11

H10

H11

H10

- 1 Discus intervertebralis
- 2 Vertebra lumbalis
- 3 Medulla spinalis
- 4 Processus spinosus
- 5 A. iliaca interna
- 6 Colon sigmoideum
- 7 Uterus, cavitas
- 8 Cervix uteri, portio supravaginalis
- 9 Rectum, plica transversa
- 10 Os coccygis (Vertebrae coccygeae I-IV)
- 11 Uterus, ostium
- 12 Rectum, ampulla
- 13 Lig. anococcygeum
- 14 M. sphincter ani externus
- 15 M. sphincter ani internus
- 16 Vagina
- 17 Labium minus pudendi
- 18 Labium majus pudendi
- 19 Clitoris, corpus cavernosum
- 20 Urethra feminina
- 21 Symphysis pubica (discus interpubicus)
- 22 Vesica urinaria
- 23 Uterus, fundus
- 24 V. iliaca externa
- 25 A. iliaca externa
- 26 V. ovarica
- 27 A. ovarica
- 28 A. mesenterica inferior
- 29 A. renalis
- 30 Aorta, pars abdominalis
- 31 V. cava inferior
- 32 Crista iliaca
- 33 Ovarium
- 34 Uterus, facies intestinalis
- 35 Ureter sinister
- 36 Vagina
- 37 M. sphincter ani externus
- 38 Glandula vestibularis major (BARTHOLINI)
- 39 Vagina, bulbus vaginae
- 40 Clitoris
- 41 Os pubis
- 42 Vesica urinaria
- 43 Uterus, lig. teres
- 44 V. iliaca externa
- 45 A. iliaca externa
- 46 Peritoneum viscerale
- 47 Ureter dexter
- 48 M. rectus abdominis
- 49 Tuba uterina (Salpinx)
- 50 Uterus
- 51 Tuba uterina, ampulla
- 52 Ovarium, lig. proprium
- 53 Uterus, lig. teres
- 54 M. rectus abdominis
- 55 Ureter
- 56 M. obliquus externus abdominis
- 57 M. obliquus internus abdominis
- 58 M. transversus abdominis
- 59 Ren, pelvis
- 60 Ren, cortex
- 61 M. latissimus dorsi
- 62 M. quadratus lumborum
- 63 M. psoas major
- 64 M. erector spinae
- 65 M. psoas minor
- 66 Ovarium, lig. proprium
- 67 Ovarium

Latin

H11

- 1 Discus intervertebralis
- 2 Vertebra lumbalis
- 3 Medulla spinalis
- 4 Processus spinosus
- 5 A. iliaca interna
- 6 Colon sigmoideum
- 7 Vesica urinaria, tunica muscularis
- 8 Vesica urinaria, fundus
- 9 Os coccygis (Vertebrae coccygeae I-IV)
- 10 Urethra, ostium internum
- 11 Prostata, utriculus
- 12 Lig. anococcygeum
- 13 M. sphincter ani externus
- 14 M. sphincter ani internus
- 15 Rectum, ampulla
- 16 Epididymis, cauda
- 17 M. cremaster
- 18 Testis
- 19 Epididymis, caput
- 20 Urethra masculina, ostium externum
- 21 Penis, corpus cavernosum
- 22 Urethra masculina, pars spongiosa
- 23 Penis, corpus spongiosum
- 24 Urethra masculina, pars prostatica
- 25 Symphysis pubica (discus interpubicus)
- 26 Rectum, plica transversa
- 27 Vesica urinaria, apex
- 28 A. iliaca externa
- 29 V. iliaca externa
- 30 Ureter dexter
- 31 A. mesenterica inferior
- 32 Aorta, pars abdominalis
- 33 A. renalis
- 34 Crista iliaca
- 35 Vesica urinaria
- 36 Ductus deferens
- 37 Ureter sinister
- 38 Vesicula seminalis
- 39 Vesica urinaria, tunica muscularis
- 40 Prostata
- 41 M. bulbospongiosus
- 42 Epididymis, caput
- 43 Epididymis, cauda
- 44 Scrotum
- 45 Testis
- 46 Penis, glans
- 47 Penis
- 48 Plexus pampiniformis
- 49 A. testicularis
- 50 Os pubis
- 51 Peritoneum viscerales
- 52 M. rectus abdominis
- 53 Vesica urinaria
- 54 Ductus deferens
- 55 Ureter dexter
- 56 A. testicularis dextra
- 57 V. testicularis dextra
- 58 M. rectus abdominis
- 59 M. obliquus externus abdominis, aponeurosis
- 60 M. obliquus internus abdominis
- 61 M. transversus abdominis
- 62 Ren, pelvis
- 63 Ren, cortex
- 64 M. quadratus lumborum
- 65 M. latissimus dorsi
- 66 M. erector spinae
- 67 M. psoas major

Pelvic Sections

English

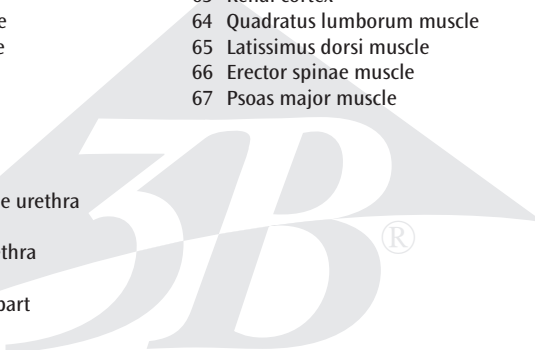
H10

Female Pelvis, 2-part

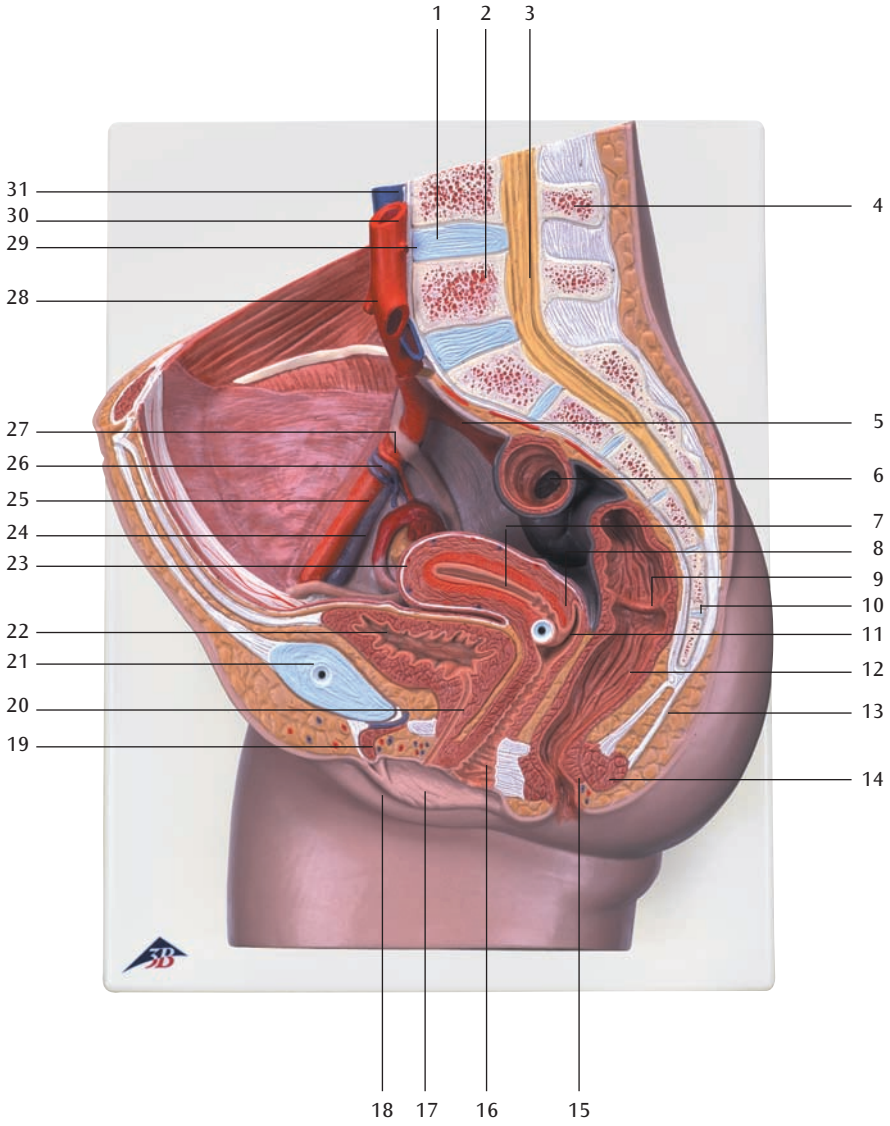
- 1 Intervertebral disc
- 2 Lumbar vertebra
- 3 Spinal marrow
- 4 Spinous process
- 5 Internal iliac artery
- 6 Sigmoid colon (pelvic colon)
- 7 Uterine cavity
- 8 Supravaginal part of cervix uteri
- 9 Transverse rectal fold
- 10 Coccygeal bone
- 11 Opening of uterus
- 12 Rectal ampulla
- 13 Anococcygeal ligament
- 14 Sphincter ani externus muscle
- 15 Sphincter ani internus muscle
- 16 Vagina
- 17 Lesser pudendal lip
- 18 Greater pudendal lip
- 19 Cavernous body of clitoris
- 20 Feminine urethra
- 21 Pubic symphysis
- 22 Bladder
- 23 Fundus of uterus
- 24 External iliac vein
- 25 External iliac artery
- 26 Ovarian vein
- 27 Ovarian artery
- 28 Inferior mesenteric artery
- 29 Renal artery
- 30 Abdominal aorta
- 31 Inferior vena cava
- 32 Crest of ilium
- 33 Ovary
- 34 Intestinal surface of uterus
- 35 Left ureter
- 36 Vagina
- 37 Sphincter ani externus muscle
- 38 Greater vestibular gland (BARTHOLINI)
- 39 Vestibula of vagina
- 40 Clitoris
- 41 Pubic bone
- 42 Bladder
- 43 Round ligament of uterus
- 44 External iliac vein
- 45 External iliac artery
- 46 Visceral peritoneum
- 47 Right ureter
- 48 Rectus abdominis muscle
- 49 Ovarian canal (uterine tube)
- 50 Uterus
- 51 Ampulla of uterine tube
- 52 Ovarian ligament
- 53 Round ligament of uterus
- 54 Rectus abdominis muscle
- 55 Ureter
- 56 Obliquus externus abdominis muscle
- 57 Obliquus internus abdominis muscle
- 58 Transversus abdominis muscle
- 59 Renal pelvis
- 60 Renal cortex
- 61 Latissimus dorsi muscle
- 62 Quadratus lumborum muscle
- 63 Psoas major muscle
- 64 Erector spinae muscle
- 65 Psoas minor muscle
- 66 Ovarian ligament
- 67 Ovary

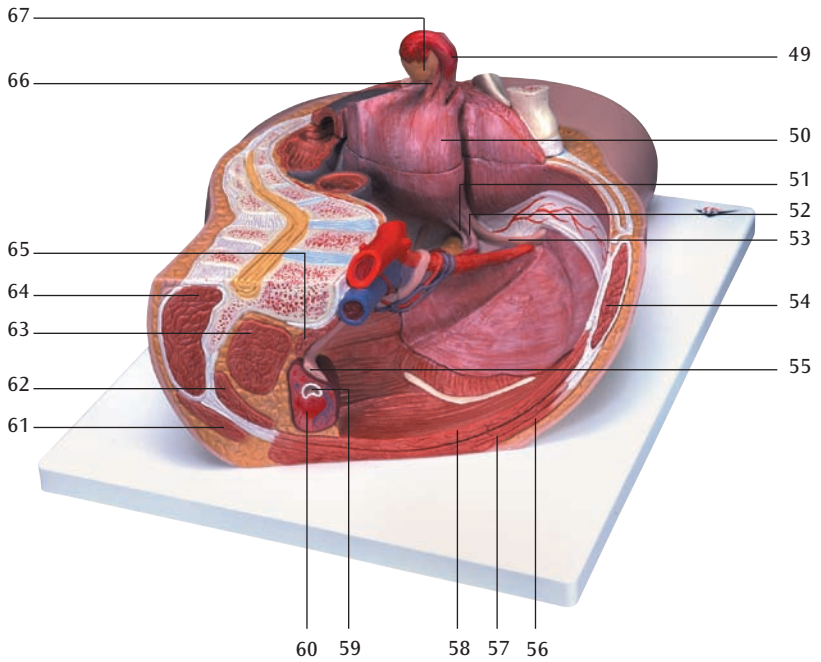
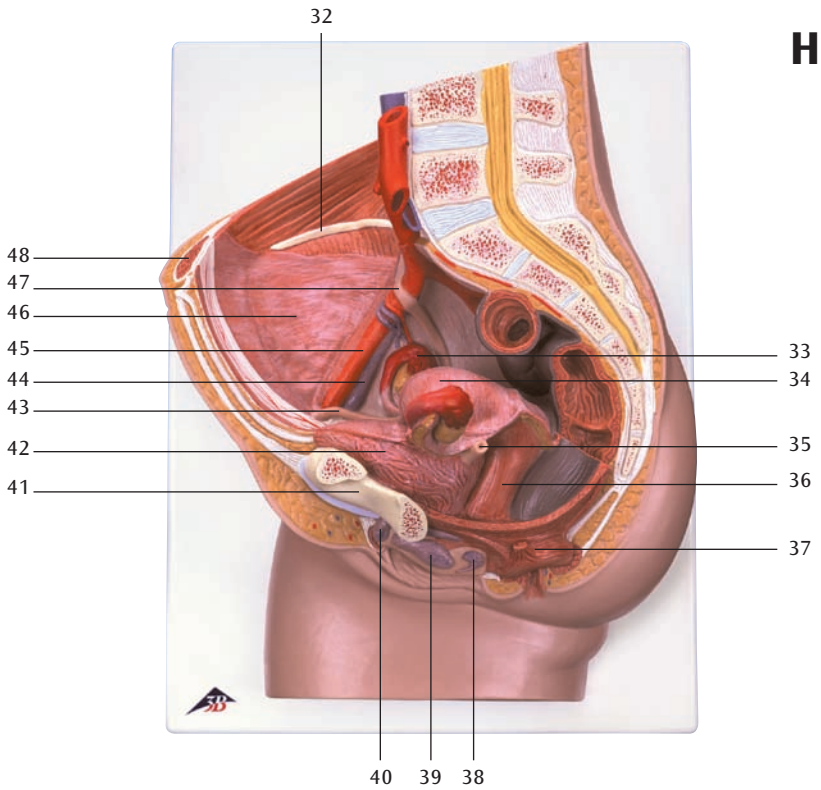
H11

Male Pelvis, 2-part

- 
- 1 Intervertebral disc
 - 2 Lumbar vertebra
 - 3 Spinal marrow
 - 4 Spinous process
 - 5 Internal iliac artery
 - 6 Sigmoid colon (pelvic colon)
 - 7 Muscular coat of bladder
 - 8 Fundus of bladder (Vortex of bladder)
 - 9 Coccygeal bone
 - 10 Internal urethral orifice
 - 11 Prostatic utricle
 - 12 Anococcygeal ligament
 - 13 Sphincter ani externus muscle
 - 14 Sphincter ani internus muscle
 - 15 Rectal ampulla
 - 16 Cauda of epididymis
 - 17 Cremaster muscle
 - 18 Testis
 - 19 Head of epididymis
 - 20 External opening of masculine urethra
 - 21 Cavernous body of penis
 - 22 Spongy part of masculine urethra
 - 23 Spongy body of penis
 - 24 Masculine urethra, prostatic part
 - 25 Pubic symphysis
 - 26 Transverse rectal fold
 - 27 Apex of urinary bladder
 - 28 External iliac artery
 - 29 External iliac vein
 - 30 Right ureter
 - 31 Inferior mesenteric artery
 - 32 Abdominal aorta
 - 33 Renal artery
 - 34 Crest of ilium
 - 35 Bladder
 - 36 Deferent duct (spermatic duct)
 - 37 Left ureter
 - 38 Seminal vesicle
 - 39 Muscular coat of bladder
 - 40 Prostate
 - 41 Bulbospongiosus muscle
 - 42 Head of epididymis
 - 43 Cauda of epididymis
 - 44 Scrotum
 - 45 Testis
 - 46 Glans of penis
 - 47 Penis
 - 48 Spermatic plexus
 - 49 Testicular artery
 - 50 Pubic bone
 - 51 Visceral peritoneum
 - 52 Rectus abdominis muscle
 - 53 Bladder
 - 54 Deferent duct (spermatic duct)
 - 55 Right ureter
 - 56 Right testicular artery
 - 57 Right testicular vein
 - 58 Rectus abdominis muscle
 - 59 Aponeurosis of obliquus externus abdominis muscle
 - 60 Obliquus internus abdominis muscle
 - 61 Transversus abdominis muscle
 - 62 Renal pelvis
 - 63 Renal cortex
 - 64 Quadratus lumborum muscle
 - 65 Latissimus dorsi muscle
 - 66 Erector spinae muscle
 - 67 Psoas major muscle

H10





H11

