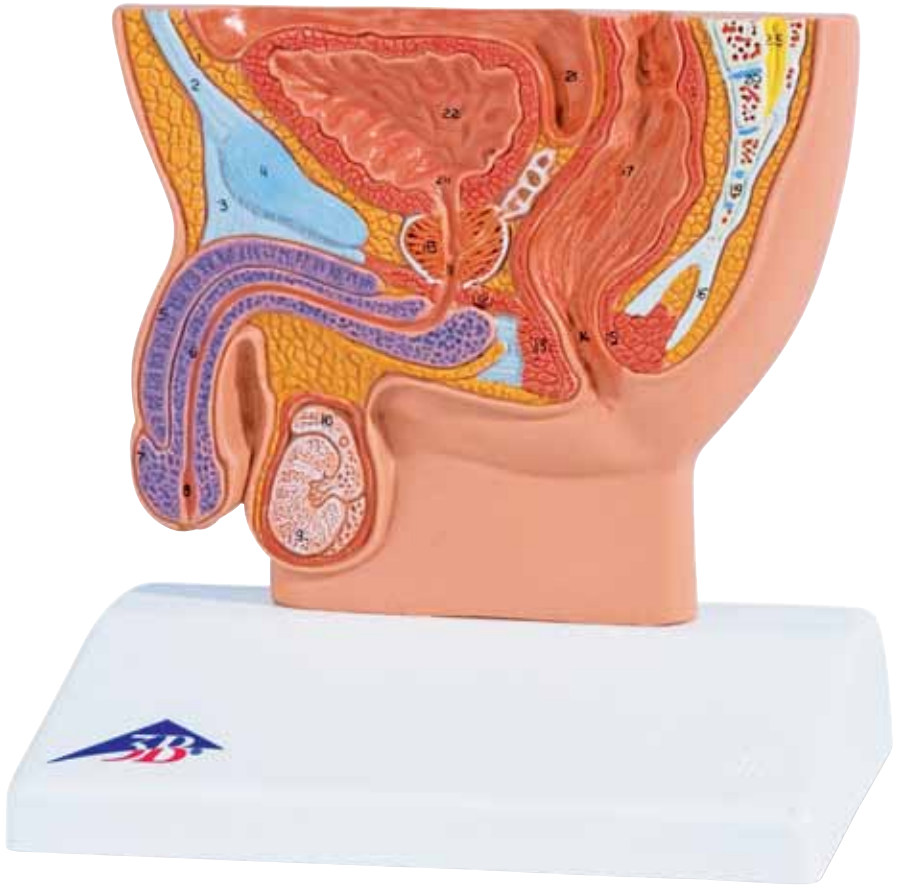




...going one step further




H12

(1000283)

Latin

- 1 Spatium retropubicum
- 2 Linea alba
- 3 Ligamentum fundiforme penis
- 4 Symphysis pubica
- 5 Corpus cavernosum penis
- 6 Corpus spongiosum penis
- 7 Glans penis
- 8 Fossa navicularis urethrae, ostium urethrae externum
- 9 Testis
- 10 Epididymis
- 11 Urethra, pars membranacea
- 12 M. transversus perinei profundus
- 13 M. sphincter ani externus
- 14 Anus
- 15 M. sphincter ani internus
- 16 Ligamentum anococcygeum
- 17 Ampulla recti
- 18 Prostata
- 19 Os coccygeum
- 20 Os sacrum
- 21 Excavatio rectovesicalis
- 22 Vesica urinaria
- 23 Ostium ureteris
- 24 Ostium urethrae internum
- 25 Filum terminale



Male Pelvis, Section

English

- 1 Retropubic space, Retzius's space
- 2 White line of abdomen/Hunter's line
- 3 Fundiform ligament of penis
- 4 Pubic symphysis
- 5 Cavernous body of penis
- 6 Spongy body of male urethra
- 7 Glans of penis
- 8 Navicular fossa of male urethra, external orifice of urethra
- 9 Testicle
- 10 Epididymis
- 11 Membranous part of urethra
- 12 Deep transverse perineal muscle
- 13 External sphincter muscle of anus
- 14 Anus
- 15 Internal sphincter muscle of anus
- 16 Anococcygeal ligament
- 17 Rectal ampulla
- 18 Prostate gland
- 19 Coccygeal bone
- 20 Sacral bone
- 21 Rectovesical pouch, rectovesical excavation
- 22 Urinary bladder
- 23 Orifice of ureter
- 24 Internal orifice of male urethra
- 25 Terminal filament

