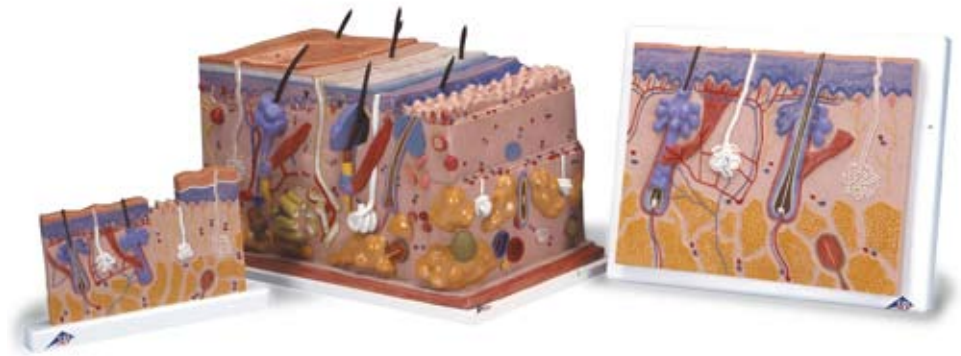



*...going one step further*



**J11**

**J13**

**J10**

**J10**

**J11**

**J13**

## Latin

### J10

- I Epidermis
- II Dermis
- III Subcutis
- 1 Glandula sebacea
- 2 Radix pili
- 3 Scapus pili
- 4 M. arrector pili
- 5 Corpusculum tactus (MEISSNER)
- 6 Porus sudorifer
- 7 Corpusculum lamellosum (VATER-PACINI)
- 8 Vagina radice externa
- 9 Vagina radice interna
- 10 Cuticula pili
- 11 Bulbus pili
- 12 Medulla pili
- 13 Cortex pili
- 14 Cellulae adiposae
- 15 Papilla pili
- 16 Glandula sudorifer merocrina
- 17 Stratum reticulare
- 18 Ductus sudorifer
- 19 Stratum papillare
- 20 Stratum basale
- 21 Stratum spinosum
- 22 Stratum germinativum
- 23 Stratum granulosum
- 24 Stratum lucidum
- 25 Stratum corneum

### J11

- I Epidermis
- II Dermis
- III Subcutis
- 1 Corpusculum tactus (MEISSNER)
- 2 Stratum corneum
- 3 Stratum lucidum
- 4 Stratum granulosum
- 5 Stratum spinosum
- 6 Stratum basale
- 7 Stratum germinativum
- 8 Stratum papillare
- 9 Ductus sudorifer
- 10 Stratum reticulare
- 11 Glandula sudorifer merocrina
- 12 Corpusculum lamellosum (VATER-PACINI)
- 13 Cellulae adiposae
- 14 Vagina radice externa
- 15 Vagina radice interna
- 16 Cuticula pili
- 17 Bulbus pili
- 18 Medulla pili
- 19 Cortex pili
- 20 M. arrector pili
- 21 Radix pili
- 22 Glandula sebacea
- 23 Scapus pili
- 24 Porus sudorifer

**J13**

- I Epidermis
- II Dermis
- III Subcutis
- IV Stratum corneum
  - 1 Scapus pili
  - 2 Stratum disjunctum
  - 3 Stratum conjunctum
  - 4 Stratum lucidum
  - 5 Stratum granulosum
  - 6 Stratum spinosum
  - 7 Stratum basale
  - 8 Membrana basalis
  - 9 Plexus venosus subpapillaris
  - 10 Stratum papillare
  - 11 Rete arteriosum subpapillaris
  - 12 Stratum reticulare
  - 13 Ductus sudorifer
  - 14 Plexus venosus corii
  - 15 Rete arteriosum corii
  - 16 Radix pili
  - 17 M. arrector pili
  - 18 Vas lymphaticum
  - 19 Arteriola
  - 20 Nervus
  - 21 Venula
  - 22 Corpusculum bulboideum (KRAUSE)
  - 23 Corpusculum lamellosum (GOLGI-MAZZONI)
  - 24 Corpusculum bulboideum (RUFFINI)
  - 25 Corpusculum lamellosum (VATER-PACINI)
  - 26 A. papillaris
  - 27 V. papillaris
  - 28 Cortex pili
  - 29 Medulla pili
  - 30 Glandula sudorifer merocrina
  - 31 Vagina epithelialis radicularis externa
  - 32 Stratum epitheliale externum
  - 33 Stratum epitheliale internum
  - 34 Cuticula pili
  - 35 Radix pili
  - 36 Glandula sebacea
  - 37 Portio terminalis glandulae sudoriferae apocrinae
  - 38 N. papillaris
  - 39 N. pili
  - 40 Fascia
  - 41 Musculus
  - 42 Cellulae adiposae
  - 43 M. arrector pili
  - 44 Corpusculum tactus (MEISSNER)
  - 45 Porus sudorifer
  - 46 Melanozyt
  - 47 Ductus sudoriferus
  - 48 Corpusculum tactus (MERKEL)

## J10

### Skin Section, 70 times full-size

- I Epidermis
- II Derma
- III Subcutis
- 1 Sebaceous gland
- 2 Root of hair
- 3 Hair shaft
- 4 Arrector muscle of hair
- 5 MEISSNER's tactile corpuscle
- 6 Sweat pore
- 7 VATER-PACINI corpuscle
- 8 Outer root sheath
- 9 Inner root sheath
- 10 Hair cuticle
- 11 Hair bulb
- 12 Medulla of hair
- 13 Cortex of hair
- 14 Adipose cell
- 15 Hair papilla
- 16 Sweat gland
- 17 Reticular layer of dermis
- 18 Sudoriferous duct
- 19 Papillary layer of dermis
- 20 Basal layer of epidermis
- 21 Spinous layer of epidermis
- 22 Stratum germinativum
- 23 Granular layer of epidermis
- 24 Clear layer of epidermis
- 25 Horny layer of epidermis

## J11

### Skin Section, 40 times full-size

- A Section of the scalp
- B Section of the sole of the foot
- I Epidermis
- II Derma
- III Subcutis
- 1 MEISSNER's tactile corpuscle
- 2 Horny layer of epidermis
- 3 Clear layer of epidermis
- 4 Granular layer of epidermis
- 5 Spinous layer of epidermis
- 6 Basal layer of epidermis
- 7 Stratum germinativum
- 8 Papillary layer of dermis
- 9 Sudoriferous duct
- 10 Reticular layer of dermis
- 11 Sweat gland
- 12 VATER-PACINI corpuscle
- 13 Adipose cell
- 14 Outer root sheath
- 15 Inner root sheath
- 16 Hair cuticle
- 17 Hair bulb
- 18 Medulla of hair
- 19 Cortex of hair
- 20 Arrector muscle of hair
- 21 Root of hair
- 22 Sebaceous gland
- 23 Hair shaft
- 24 Sweat pore

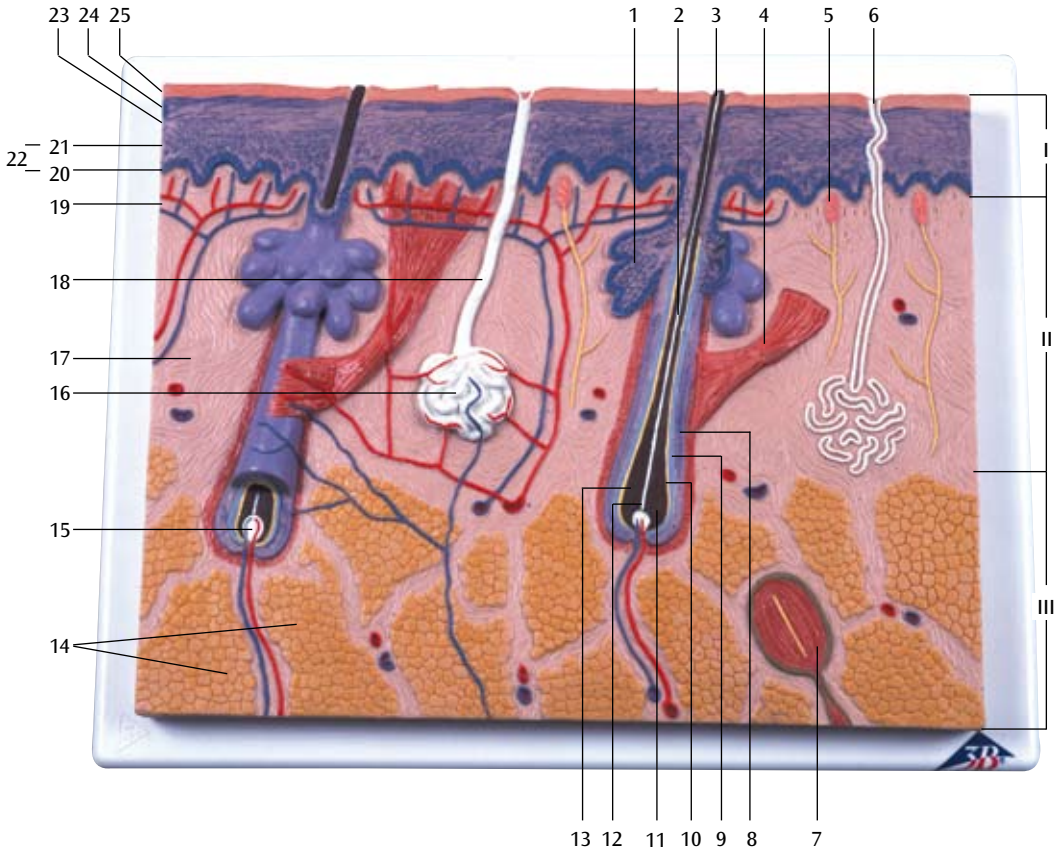
## J13

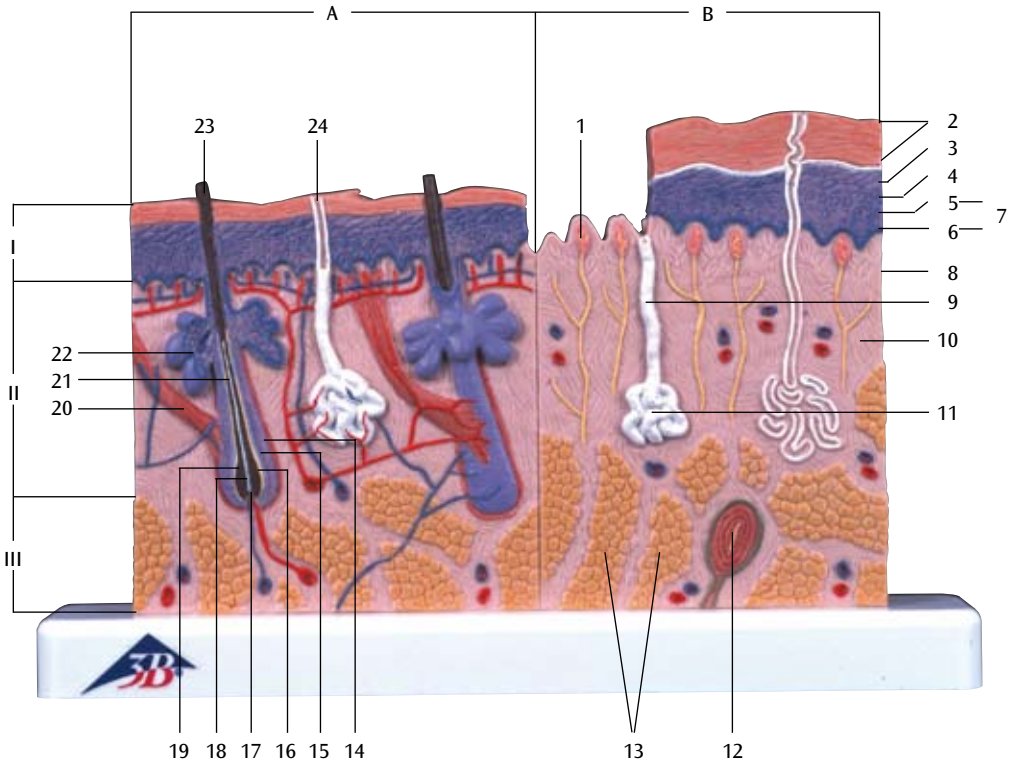
### Skin, Block Model, 70 times full-size

- I Epidermis
- II Derma
- III Subcutis
- IV Horny layer of epidermis
  - 1 Hair shaft
  - 2 Stratum disjunctum
  - 3 Stratum conjunctum
  - 4 Clear layer of epidermis
  - 5 Granular layer of epidermis
  - 6 Spinous layer of epidermis
  - 7 Basal layer of epidermis
  - 8 Basement membrane
  - 9 Subpapillary venous plexus
  - 10 Papillary layer of dermis
  - 11 Subpapillary arterial network
  - 12 Reticular layer of dermis
  - 13 Sudoriferous duct
  - 14 Venous plexus of corium
  - 15 Arterial network of corium
  - 16 Root of hair
  - 17 Arrector muscle of hair
  - 18 Lymph vessel
  - 19 Arteriole
  - 20 Nerve
  - 21 Venula
  - 22 Krause's corpuscle
  - 23 Golgi-Mazzoni corpuscles
  - 24 Brushes of Ruffini
  - 25 VATER-PACINI corpuscle
  - 26 Papillary artery
  - 27 Papillary vein
  - 28 Cortex of hair
  - 29 Medulla of hair
  - 30 Sweat gland
  - 31 Outer epithelial sheath
  - 32 Henle's layer
  - 33 Huxley's layer
  - 34 Hair cuticle
  - 35 Root of hair
  - 36 Sebaceous gland
  - 37 Body of apocrine sudoriferous gland
  - 38 Papillary nerve
  - 39 Hair nerve
  - 40 Fascia
  - 41 Muscle
  - 42 Adipose cell
  - 43 Arrector muscle of hair
  - 44 MEISSNER's tactile corpuscle
  - 45 Sweat pore
  - 46 Melanocyte
  - 47 Duct of apocrine sudoriferous gland
  - 48 Mekel's corpuscles



# J10





# J13

