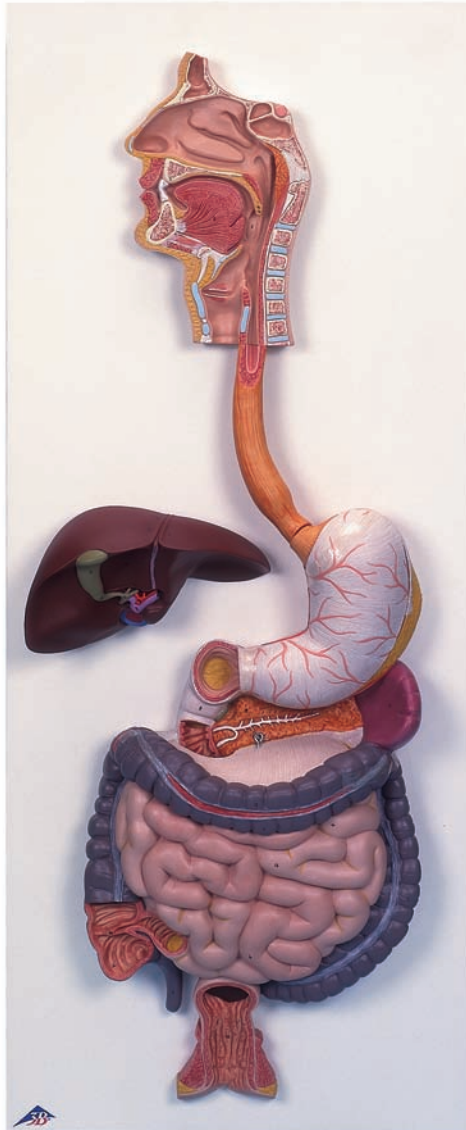




...going one step further



K20

K21

Latin

- 1 Dens
- 2 Lingua
- 3 Palatum durum
- 4 Palatum molle
- 4a Uvula palatina
- 5 Pharynx
- 6 Oesophagus
- 7 Gaster
- 7a Cardia
- 7b Fundus gastricus
- 7c Curvatura minor
- 7d Curvatura major
- 7e Pylorus
- 8 Duodenum
- 9 Pancreas
- 10 Splen
- 11 Vesica biliaris
- 12 Hepar
- 12a Lobus hepatis dexter
- 12b Lobus hepatis sinister
- 12c Lobus quadratus
- 12d Ductus cysticus
- 12e Ductus hepaticus communis
- 12f V. portae hepatis
- 12g A. hepatica propria
- 13 Intestinum tenue
- 13a Jejunum
- 13b Ileum
- 14 Valva ileocaecalis
- 15 Intestinum crassum
- 15a Colon ascendens
- 15b Colon transversum
- 15c Colon descendens
- 15d Caecum
- 15e Appendix vermiformis
- 16 Rectum



K20 Digestive System, 2-part

K21 Digestive System, 3-part

English

- 1 Tooth
- 2 Tongue
- 3 Hard palate
- 4 Soft palate
- 4a Palatine uvula
- 5 Pharynx
- 6 Esophagus
- 7 Stomach
- 7a Cardia
- 7b Fundus of stomach
- 7c Lesser curvature
- 7d Greater curvature
- 7e Pylorus
- 8 Duodenum
- 9 Pancreas
- 10 Spleen
- 11 Gallbladder
- 12 Liver
- 12a Right lobe of liver
- 12b Left lobe of liver
- 12c Quadrate lobe
- 12d Cystic duct
- 12e Common hepatic duct
- 12f Hepatic portal vein
- 12g Proper hepatic artery
- 13 Small intestine
- 13a Jejunum
- 13b Ileum
- 14 Ileocecal valve [Bauhin's valve]
- 15 Large intestine
- 15a Ascending colon
- 15b Transverse colon
- 15c Descending colon
- 15d Caecum
- 15e Appendix
- 16 Rectum

