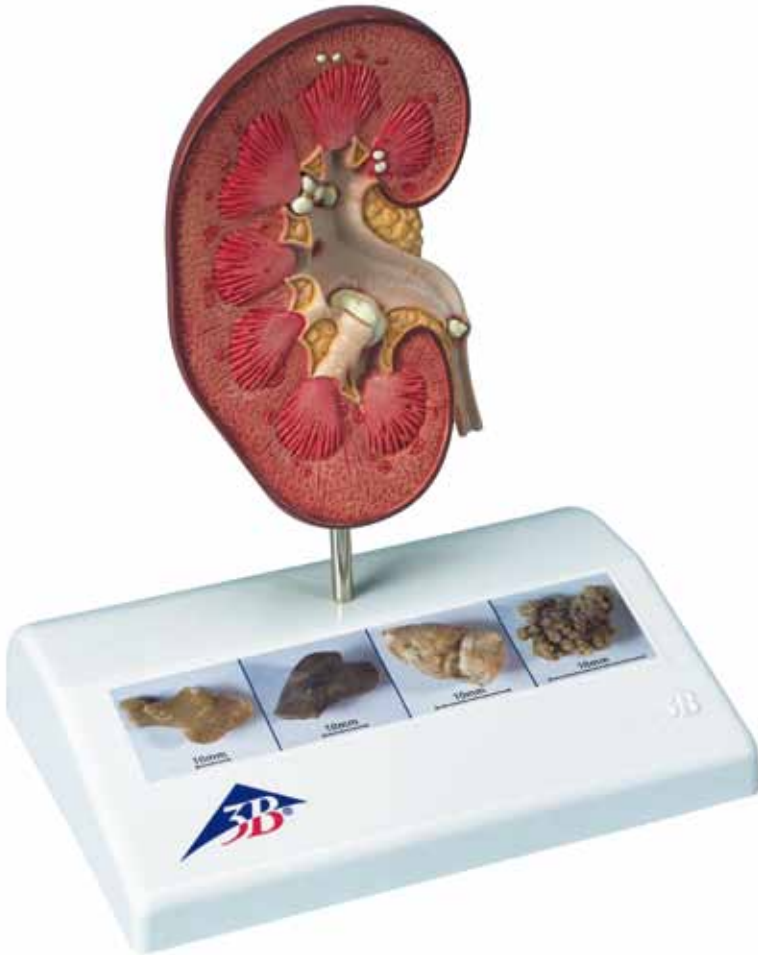




...going one step further

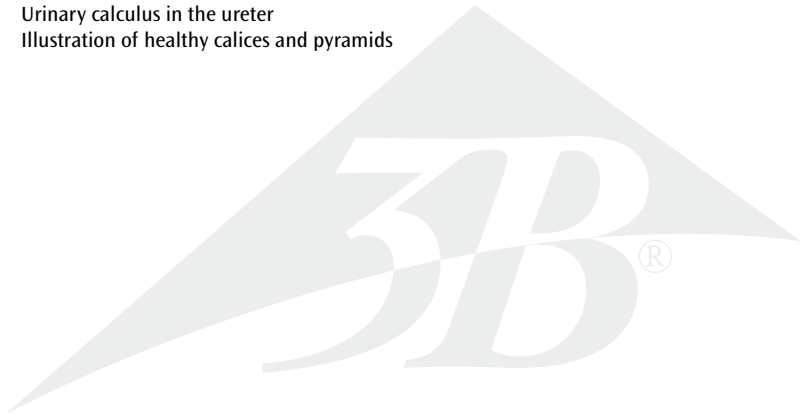


K29

(1000316)

Latin

- 1 Capsula renalis
- 2 Cortex renalis
- 3 Medulla renalis
- 4 Papilla renalis
- 5 Columnae renales
- 6 Calices renales majores
- 7 Calices renales minores
- 8 Pelvis renalis
- 9 Small concretions in the area of the renal pyramids
- 10 Concretions in the area of origin of the upper calix group
- 11 Small concretions in the renal cortex
- 12 Large concretion in the connecting tubule of the lower calix group, causing congestion of the minor calices (partially closed, partially opened)
- 13 Urinary calculus in the ureter
- 14 Illustration of healthy calices and pyramids



Kidney Stone Model

English

Nephrolithiasis and urolithiasis are characterized by deposition of hard formations (concretions). These are caused in different ways and take a variety of shapes. Single or several concretions (up to branched concretions) may occur both in the organ tissue of the kidney and in the hollow drainage system of the renal calices, the renal pelvis, the ureter and the bladder. This model shows a front view of a right kidney (natural size) opened in median longitudinal section. The renal calices, the renal pelvis and the ureter are opened as well.

Concretions: The illustrations on the base show various types.

- 1 Renal capsule
 - 2 Renal cortex
 - 3 Medulla of kidney
 - 4 Renal papilla
 - 5 Renal column
 - 6 Major renal calix
 - 7 Minor renal calix
 - 8 Renal pelvis
 - 9 Small concretions in the area of the renal pyramids
 - 10 Concretions in the area of origin of the upper calix group
 - 11 Small concretions in the renal cortex
 - 12 Large concretion in the connecting tubule of the lower calix group, causing congestion of the minor calices (partially closed, partially opened)
 - 13 Urinary calculus in the ureter
 - 14 Illustration of healthy calices and pyramids
- 