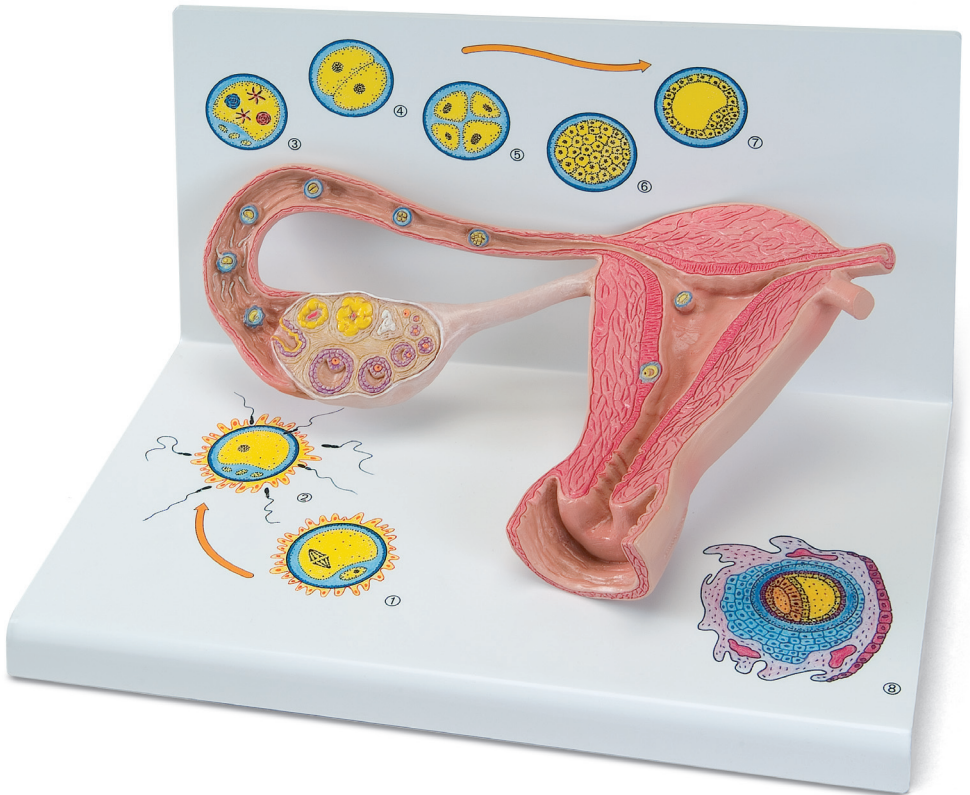




...going one step further



L01

Latin

- 1 Uterus
- 2 Cavitas uteri
- 3 Endometrium
- 4 Myometrium
- 5 Vagina
- 6 Corpus luteum
- 7 Corpus albicans
- 8 Folliculus ovaricus primordialis
- 9 Folliculus ovaricus primarius
- 10 Folliculus ovaricus secundarius
- 11 Folliculi ovarici vesiculosi
- 12 Ovarium
- 13 Folliculus ovaricus vesiculosus
- 14 Ovulatio
- 15 Impregnatio
- 16 Spermatozoon
- 17 Ovum cum pronuclei
- 18 Duo blastomeri
- 19 Quattuor blastomeri
- 20 Tuba uterina
- 21 Morula
- 22 Blastocystis
- 23 Implantatio
- 24 Oocytus secundarius
- 25 Corona radiata
- 26 Zona pellucida
- 27 Ovum
- 28 Polocytī
- 29 Blastomeri
- 30 Trophoblastus
- 31 Blastocelia
- 32 Embryoblastus
- 33 Decidua capsularis
- 34 Saccus vitellinus
- 35 Cavitas amniotica
- 36 Mesoderma
- 37 Coelom



Stages of fertilisation and blastogenesis

English

The model provides a schematic representation to illustrate the maturation of ova, ovulation, fertilisation and blastogenesis up until the embryo is implanted in the wall of the womb. The stages of development can be seen in large-scale models inside the ovary, the fallopian tubes and the womb. In some cases, even larger scale versions can be seen on the base.

Inside the ovary, primordial, primary, secondary and tertiary follicles can all be seen as well as a split tertiary follicle and a yellow body (corpus luteum).

In the fallopian tube near the ovary there is a recently split ovum with pellucid zone and corona radiata (part of the follicular epithelium) (Fig. 1).

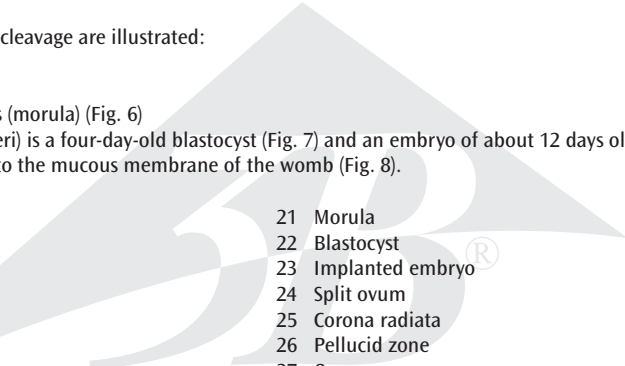
Further along in the ampulla of the uterine tube (ampulla tuba uterina), a sperm is penetrating an ova (fertilisation) (Fig. 2)

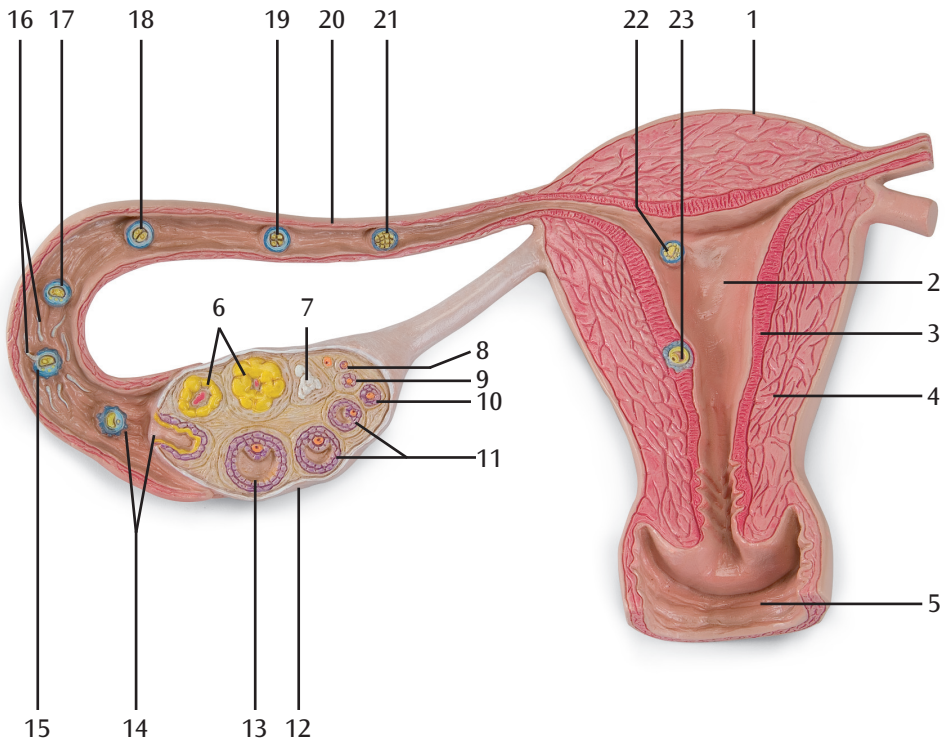
Further along the fallopian tube a fertilised ovum (zygote) is shown with both a male and a female pronucleus (Fig. 3).

The following stages of cleavage are illustrated:

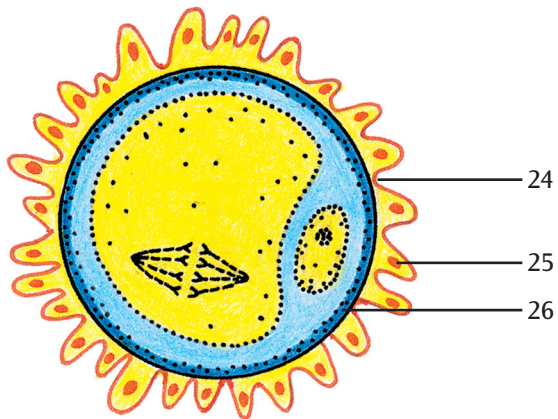
- Two-cell stage (Fig. 4)
- Four-cell stage (Fig. 5)
- Segmentation spheres (morula) (Fig. 6)

In the womb (cavitas uteri) is a four-day-old blastocyst (Fig. 7) and an embryo of about 12 days old, that is now fully implanted into the mucous membrane of the womb (Fig. 8).

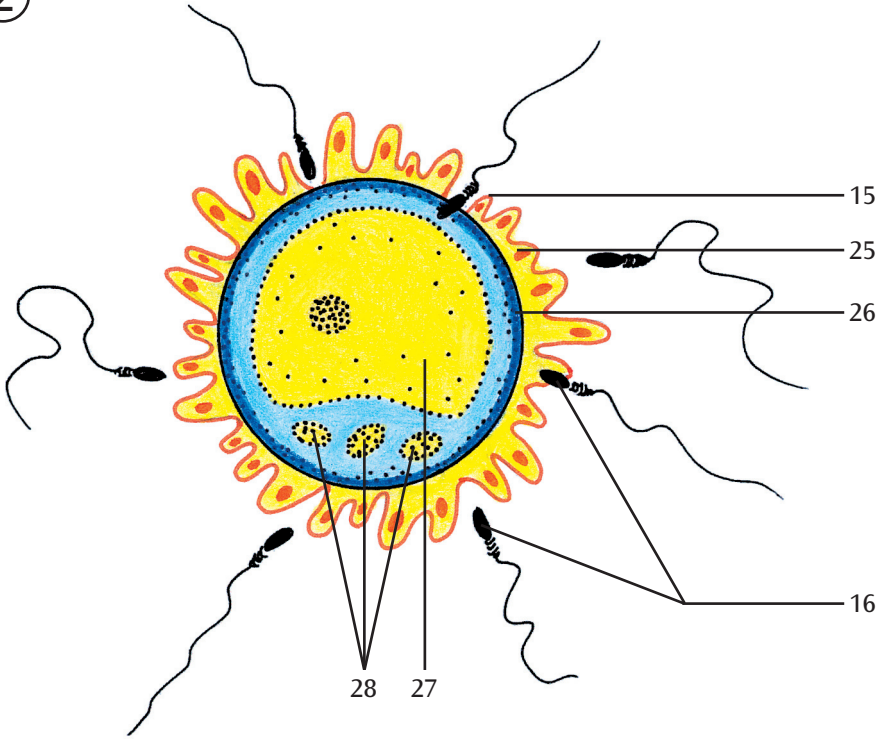
- 
- | | |
|-------------------------------|----------------------------------------------------|
| 1 Uterus | 21 Morula |
| 2 Uterine cavity | 22 Blastocyst |
| 3 Endometrium | 23 Implanted embryo |
| 4 Myometrium | 24 Split ovum |
| 5 Vagina | 25 Corona radiata |
| 6 Corpus luteum | 26 Pellucid zone |
| 7 Corpus albicans | 27 Ovum |
| 8 Primordial ovarian follicle | 28 Polar bodies |
| 9 Primary ovarian follicle | 29 Blastomere (segmentation sphere, cleavage cell) |
| 10 Secondary ovarian follicle | 30 Trophoblast |
| 11 Graafian follicles | 31 Cleavage, segmentation or subgerminal cavity |
| 12 Ovary | 32 Embryoblast (inner cell mass) |
| 13 Graafian follicle | 33 Reflex decidua |
| 14 Ovulation | 34 Yolk sack |
| 15 Fertilisation | 35 Amniotic cavity |
| 16 Spermatazoa | 36 Extraembryonic mesoderm |
| 17 Ovum with pronuclei | 37 Coelom |
| 18 Two-cell stage | |
| 19 Four-cell stage | |
| 20 Uterine tube | |



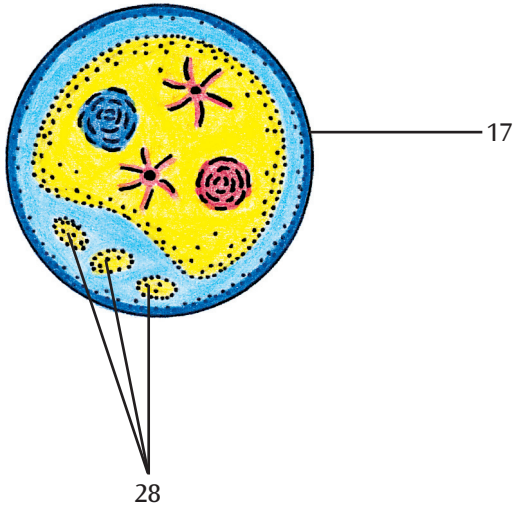
①



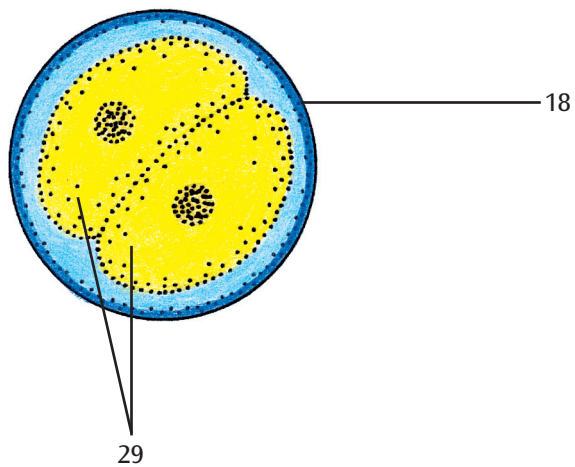
②



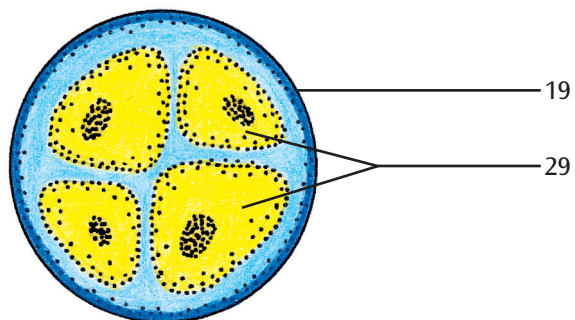
③



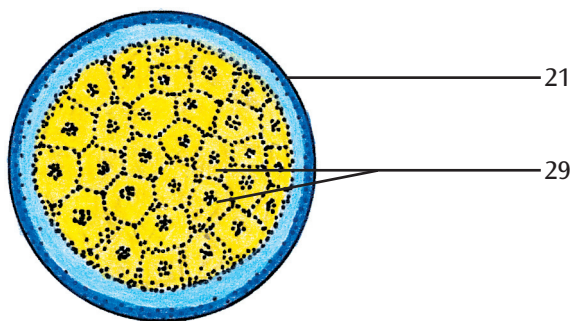
④



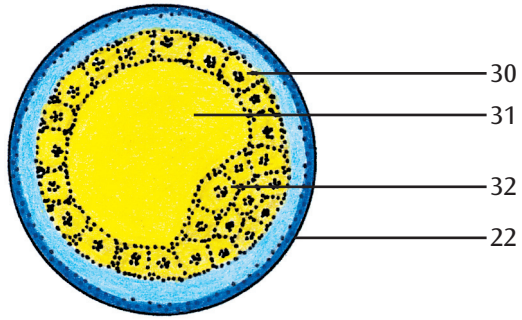
⑤



⑥



7



8

