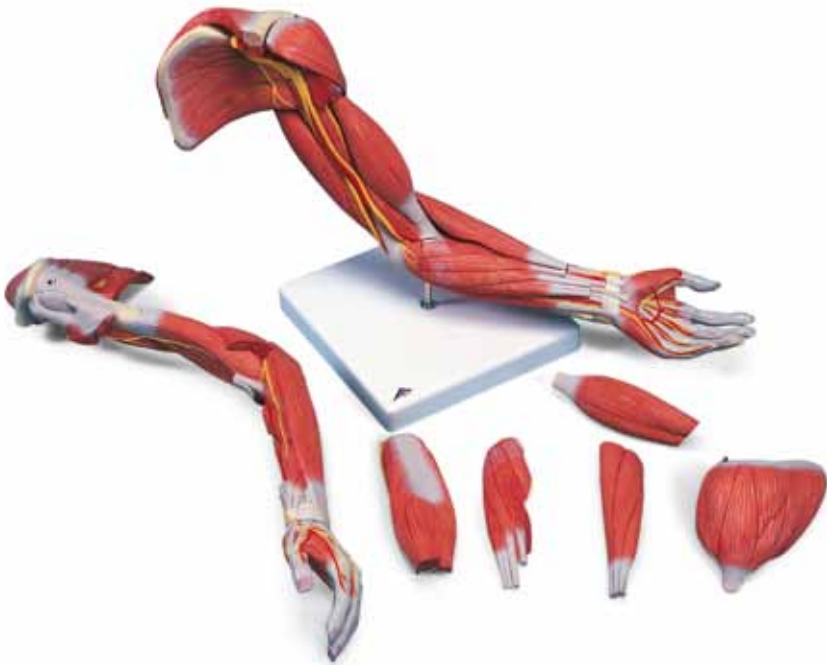

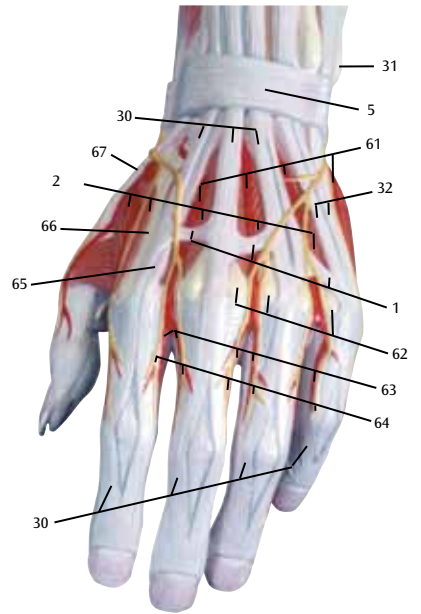
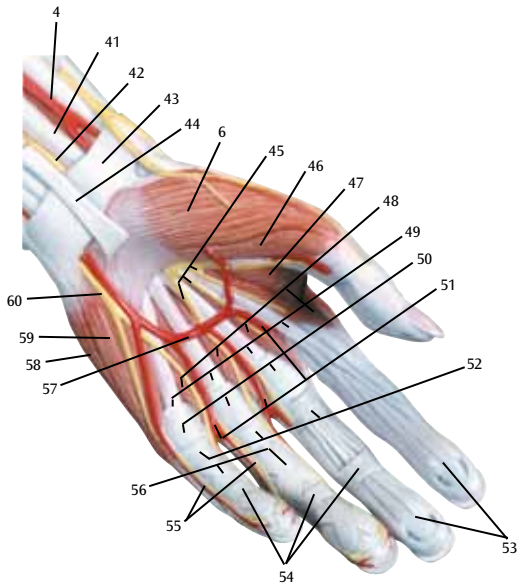
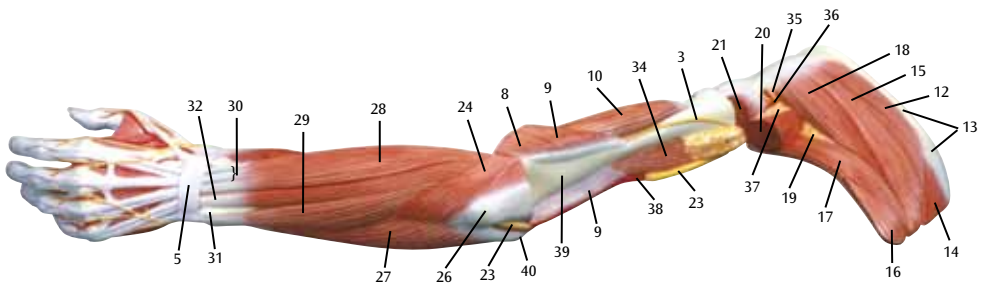
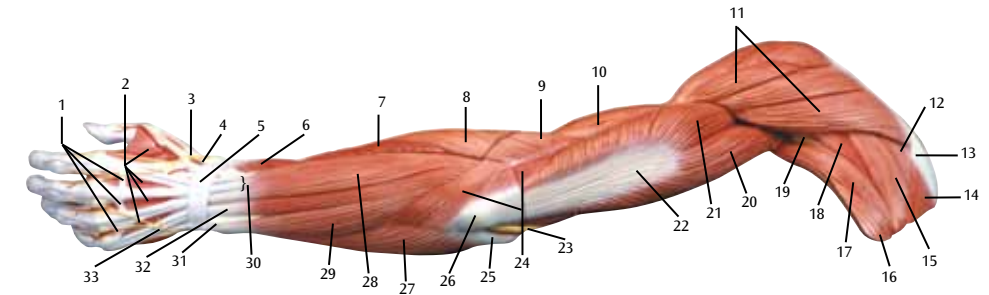


*...going one step further*



**M11**

(1000347)



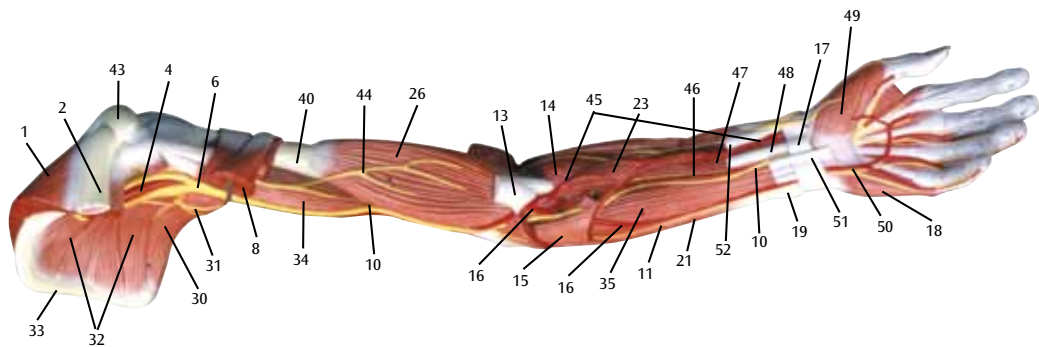
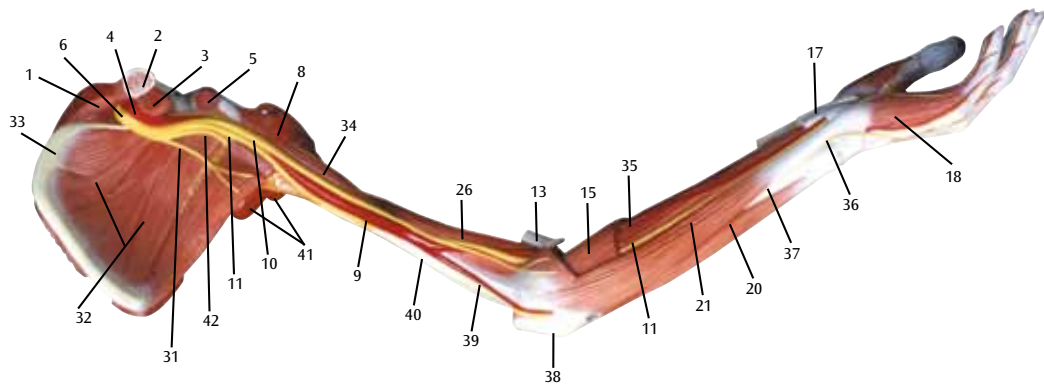
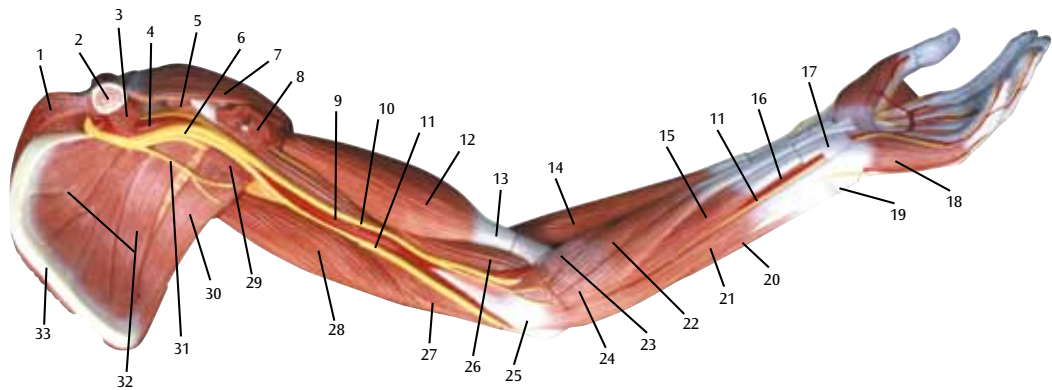
## Latin

- 1 Conexus intertendinei
- 2 Mm. interossei dorsales manus
- 3 N. radialis
- 4 A. radialis
- 5 Retinaculum extensorum
- 6 M. abductor pollicis brevis
- 7 M. extensor carpi radialis brevis
- 8 M. extensor carpi radialis longus
- 9 M. brachioradialis
- 10 M. brachialis
- 11 M. deltoideus
- 12 M. supraspinatus
- 13 Scapula, spina
- 14 M. trapezius
- 15 M. infraspinatus
- 16 M. latissimus dorsi
- 17 M. teres major
- 18 M. teres minor
- 19 Spatium axillare mediale
- 20 M. triceps brachii, caput longum
- 21 M. triceps brachii, caput laterale
- 22 M. triceps brachii, tendo
- 23 N. ulnaris
- 24 M. anconeus
- 25 Humerus, epicondylus medialis
- 26 Olecranon
- 27 M. flexor carpi ulnaris
- 28 M. extensor digitorum manus
- 29 M. extensor carpi ulnaris
- 30 M. extensor digitorum manus, tendo
- 31 Ulna, caput
- 32 M. extensor digiti minimi, tendo
- 33 N. ulnaris, ramus dorsalis
- 34 M. coracobrachialis
- 35 N. axillaris
- 36 A. circumflexa humeri posterior
- 37 Spatium axillare laterale
- 38 A. brachialis
- 39 Humerus
- 40 Humerus, epicondylus lateralis
- 41 M. flexor carpi radialis, tendo
- 42 N. medianus
- 43 Retinaculum flexorum
- 44 M. palmaris longus, tendo
- 45 N. medianus, nn. digitales palmares communes
- 46 M. flexor pollicis brevis
- 47 M. adductor pollicis
- 48 Mm. lumbricales manus
- 49 M. flexor digitorum superficialis, tendo
- 50 Lig. metacarpale transversum superficiale
- 51 Aa. digitales palmares communes
- 52 Manus, vagina tendinum digitorum
- 53 M. flexor digitorum profundus, tendo
- 54 Vaginae fibrosae, pars anularis
- 55 N. ulnaris, nn. digitales palmares proprii
- 56 Vaginae fibrosae, pars cruciforme
- 57 Arcus palmaris superficialis
- 58 M. abductor digiti minimi manus
- 59 M. opponens digiti minimi manus
- 60 N. ulnaris, ramus superficialis
- 61 Aa. metatarsales dorsales
- 62 Os metacarpale, caput
- 63 Aa. digitales dorsales manus
- 64 Nn. digitales dorsales (manus)
- 65 M. extensor indicis, tendo
- 66 Os metacarpale, corpus
- 67 M. extensor pollicis, tendo

# Muscular Arm

English

- 1 Tendinous junction
- 2 Dorsal interosseous muscles of hand
- 3 Radial nerve
- 4 Radial artery
- 5 Extensor retinaculum
- 6 Abductor pollicis brevis muscle
- 7 Extensor carpi radialis brevis muscle
- 8 Extensor carpi radialis longus muscle
- 9 Brachioradialis muscle
- 10 Brachialis muscle
- 11 Deltoideus muscle
- 12 Supraspinatus muscle
- 13 Scapular spine
- 14 Trapezius muscle
- 15 Infraspinatus muscle
- 16 Latissimus dorsi muscle
- 17 Teres major muscle
- 18 Teres minor muscle
- 19 Triangular space
- 20 Long head of triceps brachii muscle
- 21 Lateral head of triceps brachii muscle
- 22 Tendon of triceps brachii muscle
- 23 Ulnar nerve
- 24 Anconeus muscle
- 25 Medial epicondyle of humerus
- 26 Olecranon process of ulna
- 27 Flexor carpi ulnaris muscle
- 28 Extensor digitorum muscle of hand
- 29 Extensor carpi ulnaris muscle
- 30 Tendon of extensor digitorum muscle of hand
- 31 Head of ulna
- 32 Tendon of extensor digiti minimi muscle
- 33 Dorsal branch of ulnar nerve
- 34 Coracobrachialis muscle
- 35 Axillary nerve
- 36 Posterior circumflex humeral artery
- 37 Quadrangular space
- 38 Brachial artery
- 39 Humerus
- 40 Lateral epicondyle of humerus
- 41 Tendon of flexor carpi radialis muscle
- 42 Median nerve
- 43 Flexor retinaculum
- 44 Tendon of palmaris longus muscle
- 45 Common palmar digital nerves of median nerve
- 46 Flexor pollicis brevis muscle
- 47 Adductor pollicis muscle
- 48 Lumbrical muscles of hand
- 49 Tendon of flexor digitorum superficialis muscle
- 50 Superficial transverse metacarpal ligament
- 51 Common palmar digital arteries
- 52 Digital synovial sheath
- 53 Tendon of flexor digitorum profundus muscle
- 54 Annular part of fibrous tendon sheaths
- 55 Proper palmar digital nerves of ulnar nerve
- 56 Cruciform part of fibrous tendon sheaths
- 57 Superficial palmar arch
- 58 Abductor digiti minimi muscle of hand
- 59 Opponens digiti minimi muscle of hand
- 60 Superficial branch of ulnar nerve
- 61 Dorsal metatarsal arteries
- 62 Head of metacarpal bone
- 63 Dorsal digital arteries of hand
- 64 Dorsal digital nerves of fingers
- 65 Tendon of extensor indicis muscle
- 66 Body of metacarpal bone
- 67 Tendon of extensor pollicis muscle



## **Latin**

- 1 M. trapezius
- 2 Clavicula
- 3 M. subclavius
- 4 A. axillaris
- 5 M. pectoralis minor
- 6 Plexus brachialis
- 7 M. deltoideus
- 8 M. pectoralis major
- 9 A. brachialis
- 10 N. medianus
- 11 N. ulnaris
- 12 M. biceps brachii, caput breve
- 13 M. biceps brachii, tendo
- 14 M. brachioradialis
- 15 M. flexor digitorum superficialis manus
- 16 A. ulnaris
- 17 Retinaculum flexorum
- 18 M. abductor digiti minimi manus
- 19 Ulna, caput
- 20 M. extensor carpi ulnaris
- 21 M. flexor carpi ulnaris
- 22 M. flexor carpi radialis
- 23 M. pronator teres
- 24 M. palmaris longus
- 25 Humerus, epicondylus medialis
- 26 M. brachialis
- 27 M. triceps brachii, caput mediale
- 28 M. triceps brachii, caput longum
- 29 M. latissimus dorsi
- 30 M. teres major
- 31 N. thoracodorsalis
- 32 M. subscapularis
- 33 Scapula, margo medialis
- 34 M. coracobrachialis
- 35 M. flexor digitorum profundus manus
- 36 N. ulnaris, ramus dorsalis
- 37 Ulna
- 38 Olecranon
- 39 A. collateralis ulnaris inferior
- 40 Humerus
- 41 M. triceps brachii
- 42 N. radialis
- 43 Acromion
- 44 N. musculocutaneus
- 45 A. radialis
- 46 A. interossea anterior
- 47 M. pronator quadratus
- 48 M. flexor carpi radialis, tendo
- 49 M. abductor pollicis brevis
- 50 Arcus palmaris superficialis
- 51 M. palmaris longus, tendo
- 52 M. flexor pollicis longus, tendo

# Muscular arm

English

- 1 Trapezius muscle
- 2 Clavicle
- 3 Subclavius muscle
- 4 Axillary artery
- 5 Pectoralis minor muscle
- 6 Brachial plexus
- 7 Deltoideus muscle
- 8 Pectoralis major muscle
- 9 Brachial artery
- 10 Median nerve
- 11 Ulnar nerve
- 12 Short (medial) head of biceps brachii muscle
- 13 Tendon of biceps brachii muscle
- 14 Brachioradialis muscle
- 15 Flexor digitorum superficialis muscle
- 16 Ulnar artery
- 17 Flexor retinaculum
- 18 Abductor digiti minimi muscle of hand
- 19 Head of ulna
- 20 Extensor carpi ulnaris muscle
- 21 Flexor carpi ulnaris muscle
- 22 Flexor carpi radialis muscle
- 23 Pronator teres muscle
- 24 Palmaris longus muscle
- 25 Medial epicondyle of humerus
- 26 Brachialis muscle
- 27 Medial head of triceps brachii muscle
- 28 Long head of triceps brachii muscle
- 29 Latissimus dorsi muscle
- 30 Teres major muscle
- 31 Thoracodorsal nerve
- 32 Subscapularis muscle
- 33 Medial margin of scapula
- 34 Coracobrachialis muscle
- 35 Flexor digitorum profundus muscle
- 36 Dorsal branch of ulnar nerve
- 37 Ulna
- 38 Olecranon process of ulna
- 39 Inferior collateral ulnar artery
- 40 Humerus
- 41 Triceps brachii muscle
- 42 Radial nerve
- 43 Acromion (acromial bone)
- 44 Musculocutaneous nerve
- 45 Radial artery
- 46 Anterior interosseous artery
- 47 Pronator quadratus muscle
- 48 Tendon of flexor carpi radialis muscle
- 49 Abductor pollicis brevis muscle
- 50 Superficial palmar arch
- 51 Tendon of palmaris longus muscle
- 52 Tendon of flexor pollicis longus muscle