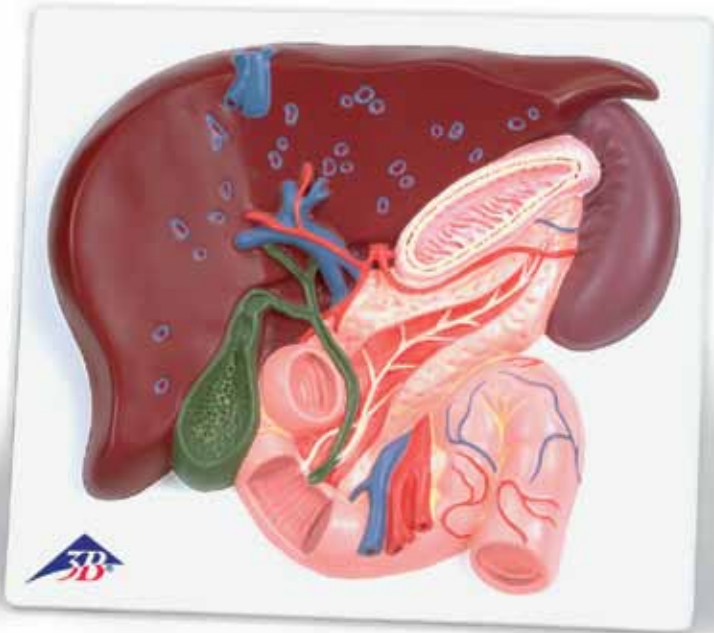




...going one step further



VE315

(1008550)

Latin

- 1 Lobus hepatis sinister
- 2 Lobus hepatis dexter
- 3 Fundus vesicae biliaris
- 4 Corpus vesicae biliaris
- 5 Collum vesicae biliaris
- 6 Plica spiralis
- 7 Caput pancreatis
- 8 Corpus pancreatis
- 9 Cauda pancreatis
- 10 Gaster
- 11 Splen
- 12 Duodenum, pars superior
- 13 Duodenum, pars descendens
- 14 Duodenum, pars horizontalis
- 15 Duodenum, pars ascendens
- 16 Plicae circulares
- 17 Jejunum
- 18 Ductus cysticus
- 19 Ductus hepaticus communis
- 20 Ductus choledochus
- 21 Ductus pancreaticus accessorius
- 22 Ductus pancreaticus
- 23 Papilla duodeni minor
- 24 Papilla duodeni major
- 25 Truncus coeliacus
- 26 A. gastrica sinistra
- 27 A. splenica
- 28 A. hepatica communis
- 29 A. hepatica propria
- 30 A. gastroduodenalis
- 31 A. mesenterica superior
- 32 V. cava inferior
- 33 Vv. hepaticae
- 34 V. portae hepatis
- 35 V. mesenterica superior



Liver Gall Bladder - Pancreas - Duodenum

English

- 1 Left lobe of liver
- 2 Right lobe of liver
- 3 Fundus of gallbladder
- 4 Body of gallbladder
- 5 Neck of gallbladder
- 6 Spiral fold
- 7 Head of pancreas
- 8 Body of pancreas
- 9 Tail of pancreas
- 10 Stomach
- 11 Spleen
- 12 Superior part of duodenum
- 13 Inferior part of duodenum
- 14 Horizontal part of duodenum
- 15 Ascending part of duodenum
- 16 Circular folds
- 17 Jejunum
- 18 Cystic duct
- 19 Common hepatic duct
- 20 Bile duct
- 21 Accessory pancreatic duct
- 22 Pancreatic duct
- 23 Minor duodenal papilla
- 24 Major duodenal papilla
- 25 Coeliac trunk
- 26 Left gastric artery
- 27 Splenic artery
- 28 Common hepatic artery
- 29 Hepatic artery proper
- 30 Gastroduodenal artery
- 31 Superior mesenteric artery
- 32 Inferior vena cava
- 33 Hepatic veins
- 34 Hepatic portal vein
- 35 Superior mesenteric vein



